

Guide to the British Veterinary Association / Kennel Club Chiari malformation / Syringomyelia (CM/SM) Scheme

2. Screening Protocol

What documentation and identification is required?

- **All dogs must be permanently identified (by microchip or tattoo)** before examination and certification. The identification will be verified by the performing vet prior to the examination and the identification number will be recorded both on the images and on the certificate issued.
- **You must have the relevant KC owner registration document/related transfer or change of name certificate** with you in order to present your dog for a MRI scan. It is possible to scan dogs that are not KC registered; an alternative appropriate form of identification must be provided (e.g. pet name, identification from your veterinary practice or breed club).
- **Owners must sign a declaration** certifying that the details are correct, and that the results may be published in the KC Breed Record Supplement and on the KC website for use with their Mate Select programme, and also used for research purposes.
- All of the above **information must be correct at the time of scanning as it is not possible to change** the details on DICOM images retrospectively.

What information must be included on the DICOM images?

The following information **MUST** be included on the DICOM images **at the time of scanning**:

(a) EITHER

- (i) the Kennel Club registration number (from the top right hand corner of the KC Registration Certificate) for dogs registered with the KC (**no other form of identification for KC registered dogs is acceptable**)
- Or
- (ii) an appropriate form of identification for dogs not registered with the KC (e.g. identification used by the owner's veterinary practice or the breed club);

(b) the dog's microchip or tattoo number, which **MUST** be confirmed by the veterinary surgeon submitting the MR images and verified on the relevant part of the CMSM certificate;

(c) the date of MRI.

NB DICOM images which are not correctly identified will be returned to the submitting veterinary surgeon and appropriately identified DICOM images requested. As this information cannot be entered retrospectively onto DICOM images it is essential that it be done correctly at the time of scanning.

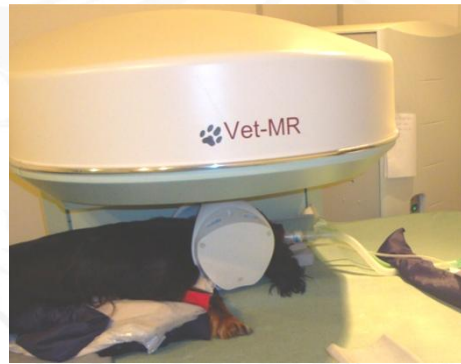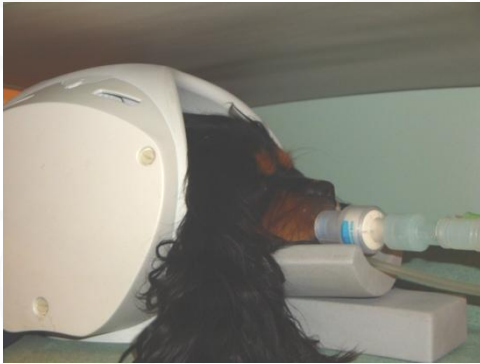The screenshot shows a software interface for patient information and anatomy examination. The 'Patient' section includes fields for Last Name, First Name, Name Prefix, Middle Name, Name Suffix, Breeder's surname, Pedigree Name, Animal Name, Call Name, Date of Birth (01/01/2005), Sex (Male), Species (Dog), Breed (CAVALIER KING), ID, and Kennel Club # Microchip#. The 'Referring Physician's Name' section includes Last Name (Rusbridge), First Name, Name Prefix, Middle Name, and Name Suffix. The 'Anatomy Examined' section shows a list of options: Cervico-Thoracic - Prone - Head on Right (selected), Carpus, Cervical, Decubitus Left, Prone, Head on Right (selected), Head on Left, and Supine. The 'Orientation' section is partially visible.

*******Important note for ESOVATE VET MRI ® users*******

Information entered in the "Animal Name" field is **NOT** incorporated in the exported DICOM images. For suggestions on how to enter information so that dog can be identified see image left.

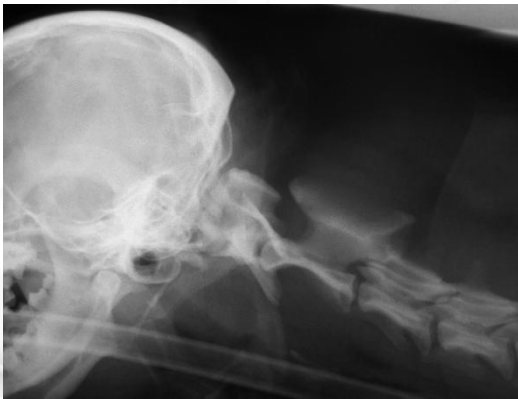How is the dog positioned?

Correct positioning is essential to provide MR images of diagnostic quality. The dog's head and neck should be in extension so that the skull base is approximately aligned with the floor of the vertebral canal through C1 and C2.

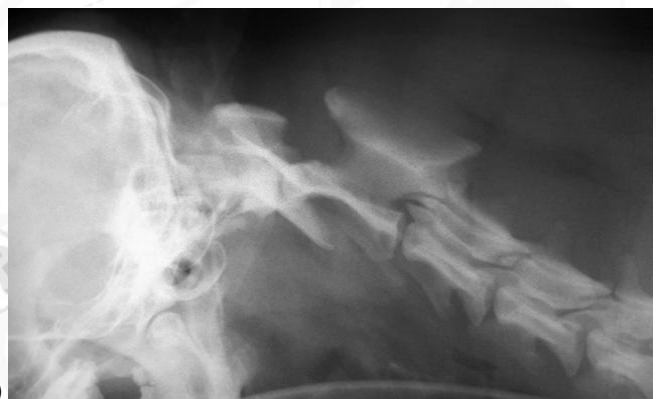

Flexion can make a CM more obvious – are flexed images not preferred?

Flexing the neck may compromise the dog if there is an undiagnosed atlantoaxial subluxation and/or obstruct the airway (windpipe). It may be difficult for vets to reproduce an ideal angulation. Therefore although obtaining views in flexion may be useful in assessment of a clinical case it is not required for screening for CMSM.



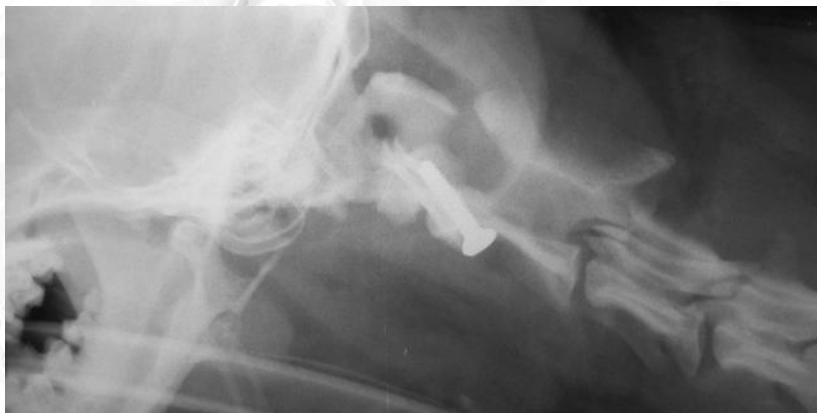a)



b)

a) Cavalier with atlantoaxial subluxation with head in extension

b) Cavalier with atlantoaxial subluxation with head in flexion. There is a laxity in the joint and when the head is flexed the spinal cord is crushed by the vertebrae.



c) Cavalier with atlantoaxial subluxation after surgical screw fixation of the joint

What MR Images are obtained?

The **minimum** required images are:

1. Sagittal T1W

- interthalamic adhesion to as far caudal in the neck as possible but at least to C4/C5 intervertebral disc space.
- The maximum slice thickness permissible is 4mm.
- The head and neck should be aligned in the sagittal plane and if this is not possible then separate sagittal images of the brain and spinal cord should be obtained so that a midline sagittal image of each is represented.

Images will be deemed non-diagnostic if the CNS from the cisterna magna to the C4/C5 intervertebral disc space is not continuously visible in a single sagittal image. The exception to this is if the dog has scoliosis, in which instance dorsal plane images of the relevant area must also be supplied. Dogs with scoliosis as a consequence of SM typically have a marked syringomyelia. If this is not the case the presence of scoliosis may be questioned and the images rejected.

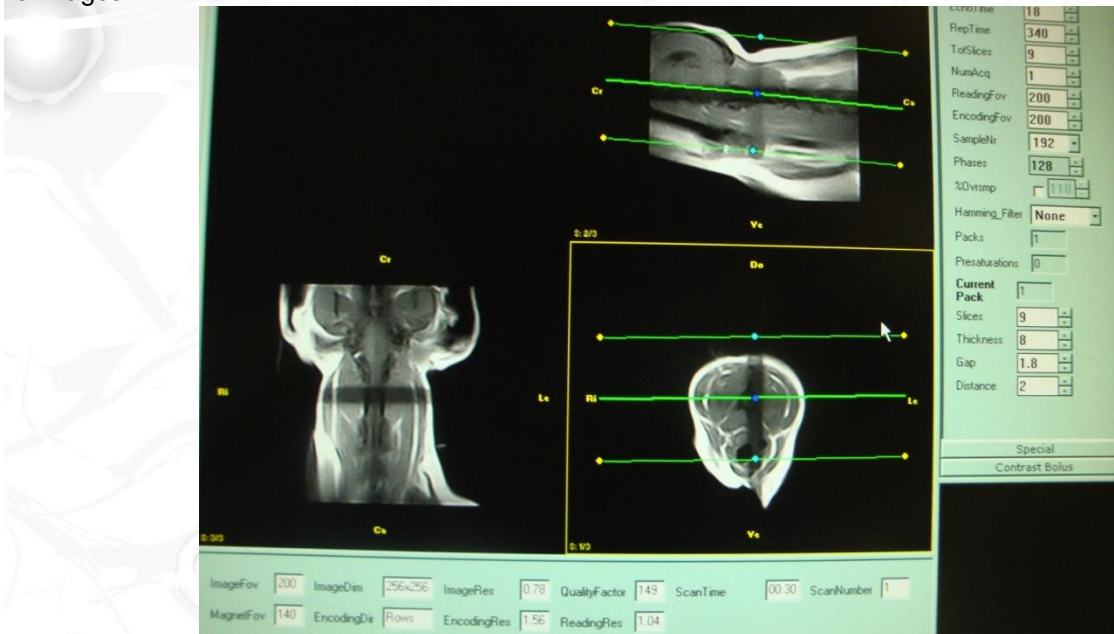
2. Sagittal T2W (as above).

3. Transverse T1W or T2W images

- perpendicular to the spinal cord
 - i. **if SM is present** though the maximum width of the syrinx
or
 - ii. **if SM not present** a block centred on C3 and extending from at least mid-point of the vertebral body of C2 and reaching at least as far caudally as the mid-point of the vertebral body of C4.
- The maximum slice thickness should be 4mm.
- T2W images are preferred for high field magnets and T1W images are preferred for low field magnets.

Tips for ensuring optimal images

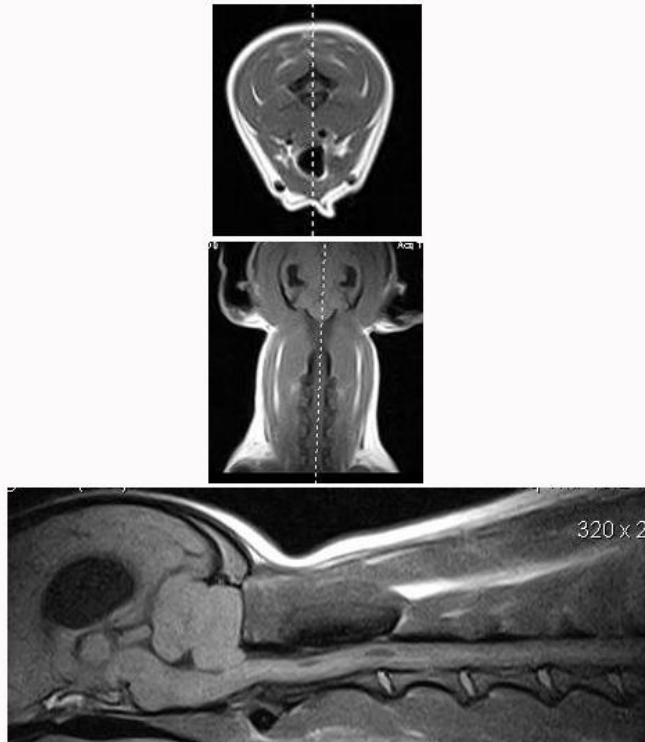
Getting it straight! Use transverse and dorsal localiser after the initial scout as a guide to correct positioning of the images.



Settings for a dorsal localisers on a ESOVATE MRI machine (29 seconds ET 18, rep time 340, slices 9, num ac 1, reading and encoding FOV 200, sample nr 192, phases 128, hamming none, slices 9, thickness 8.0, gap 1.8).

In addition to a transverse localiser this allows you to plan the sagittal shots centring on the dorsal spines of the vertebrae.

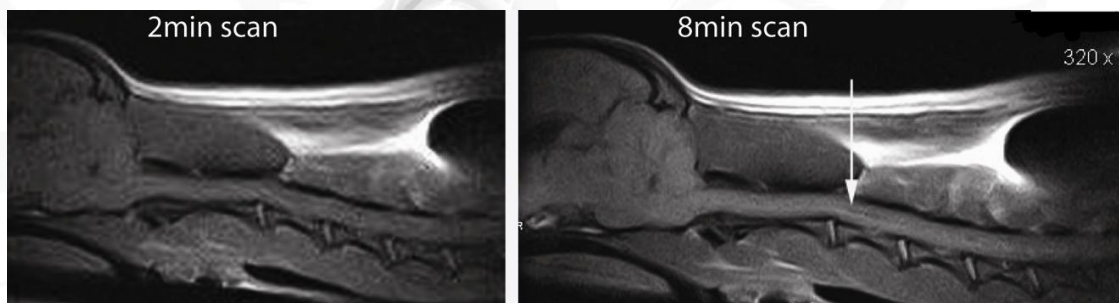
Using "Localisers" to improve imaging



A midline sagittal T1W image (lower) obtained on an ESOVATE Vet MRI machine. For the scheme the interthalamic adhesion to at least to C4/C5 intervertebral disc space should be continuously visible in a single sagittal image. Short (~ 30s) dorsal and transverse sequences were first obtained (upper images) to aid positioning.

Sagittal T1W on ESOVATE Vet MRI machines.

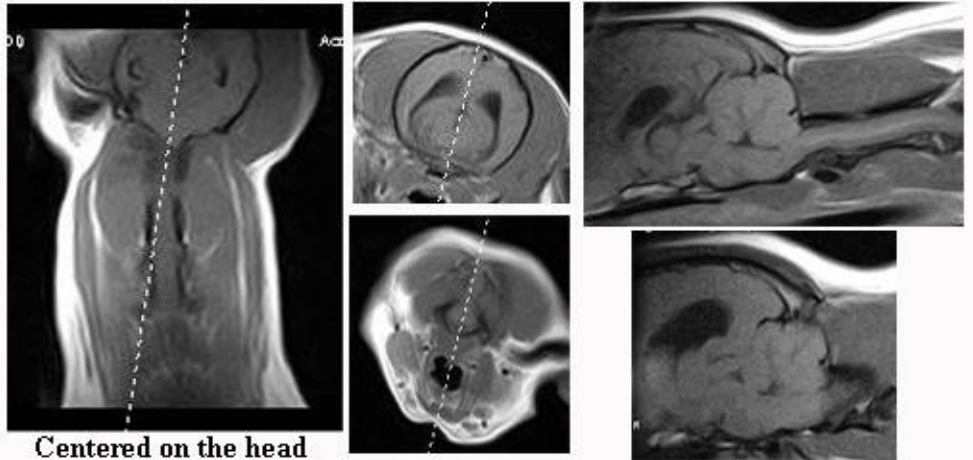
Low cost MRI screening for SM is performed in many cases on ESOVATE MRI machines. Images of excellent quality can be obtained but operators should beware of taking short cuts either for time or economic reasons. Subtle SM may be missed. The images below are taken from the same dog with a narrow syringomyelia (below). The image on the left is taken with a short acquisition times and the SM is not appreciable. The image on the right is a longer acquisition time (settings below). The consequence to the breeder of missing subtle disease may be devastating as his or her whole breeding program may be based on the assumption that the dog in question is unaffected.



Midline sagittal T1W image (lower) obtained on an ESOVATE Vet MRI machine. The image on the right was obtained using the following settings: ET 26, Rep time 530 Slices 10, Num Aq 4 Reading FOV 170, encoding FOV 170, Sample # 320, phases 232, Hamming filter low, thickness 4.5, gap 0.4. These parameters give a short field of view (FOV) and greater contrast.

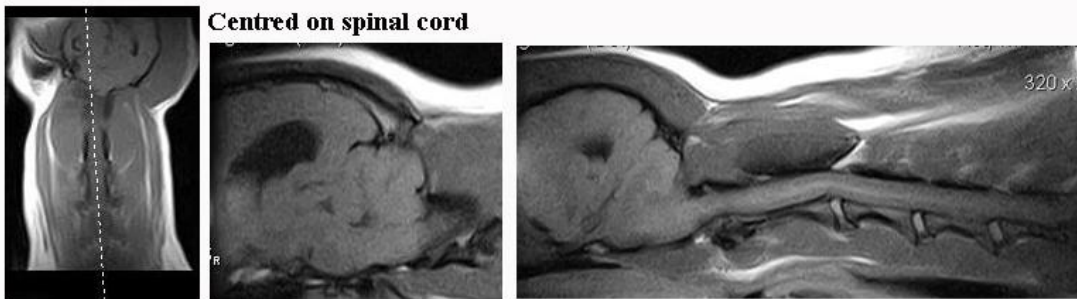
What if I can't get the head and neck straight?

It can be difficult to have the head aligned straight with the neck especially with a thin dog. In this instance 2 sets of sagittal images must be submitted one centred on the head and one centred on the spine (below).



Centered on the head

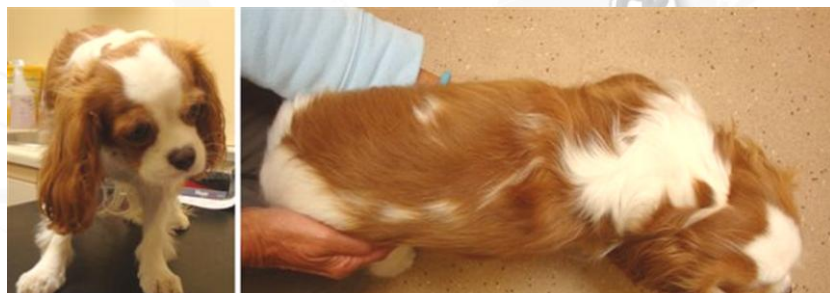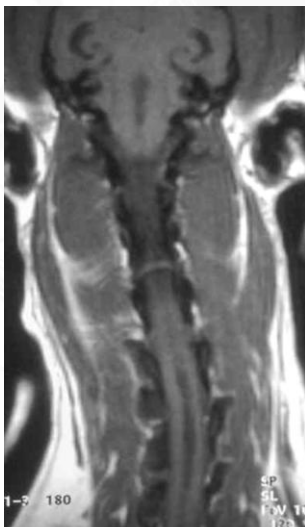
In this dog the head is tilted to the right and it is not possible to obtain a midline sagittal image where the interthalamic adhesion to C4/C5 intervertebral disc is continuously visible. Therefore an a midline sagittal image of the brain and upper spinal cord is obtained first (above) then separate imaging for a midline sagittal image of the spinal cord from C1 to C5 is performed (below).



Centred on spinal cord

If the dog has **scoliosis** then it will not be possible to obtain midline sagittal images in which instance dorsal plane images of the relevant area must also be supplied. Dogs with scoliosis as a consequence of SM typically have a marked syringomyelia. If this is not the case the presence of scoliosis may be questioned and the images rejected.

Dorsal MRI scan of a CKCS (right) with scoliosis secondary to syringomyelia



Common pitfalls

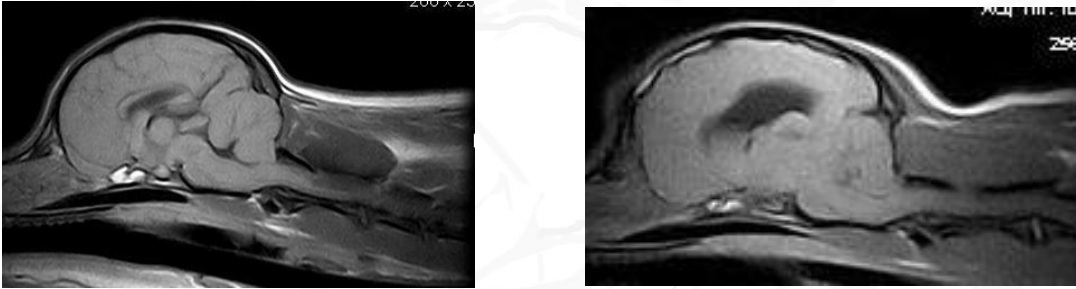
Incorrect labelling

The following information **MUST** be included on the DICOM images at the time of scanning:

- 1) the Kennel Club registration number (or an appropriate form of identification for dogs not registered with the KC)
- 2) the dog's microchip or tattoo number
- 3) the date of MRI.

For users of the ESOVATE Vet MRI data entered in the "Animal Name" field is **NOT** incorporated in the exported DICOM images.

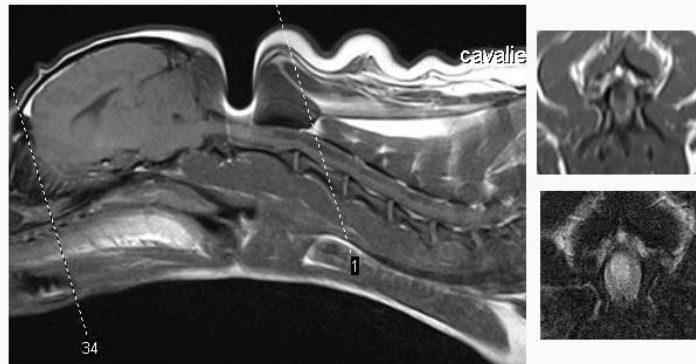
Wrong position



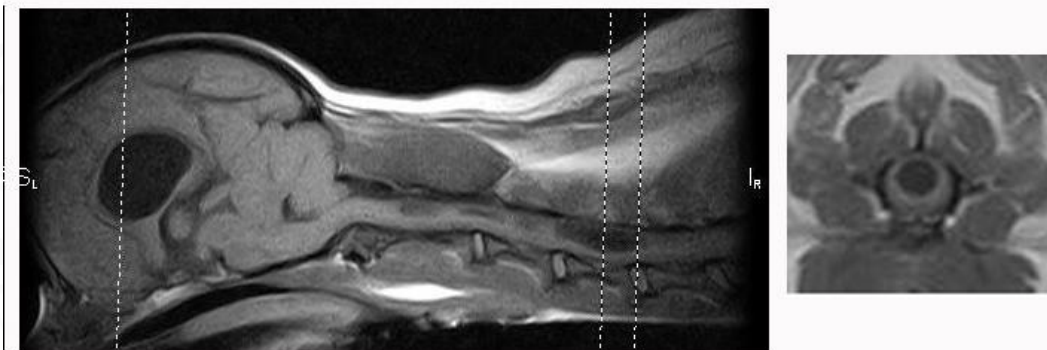
In these submitted images from two CKCS the spinal cord is only imaged to mid C4 (left) and mid C3 (right). The dog on the left has SM but it is not easily appreciable. In addition for the dog on the right the images are not midline

Transverse images not perpendicular to the spinal cord

The images below show a comparison between incorrect (top) and correct (bottom)

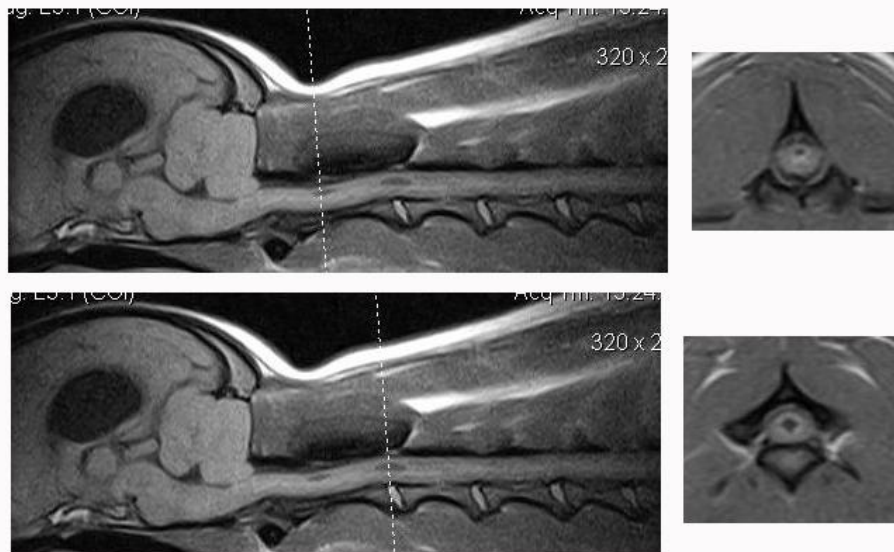


Head slightly flexed
Transverse images not perpendicular to spinal cord and not through widest part of syrinx.



King Charles spaniel with head in extension
4mm slices perpendicular to the spinal cord with 1 slice through the widest part of the syrinx

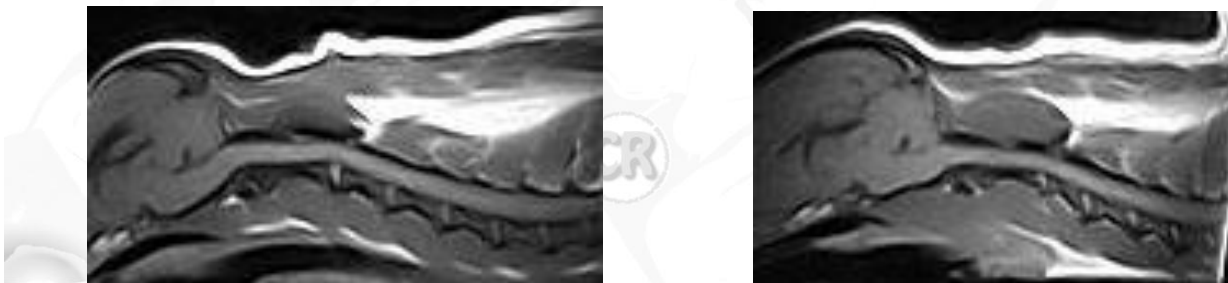Transverse images not through the syrinx



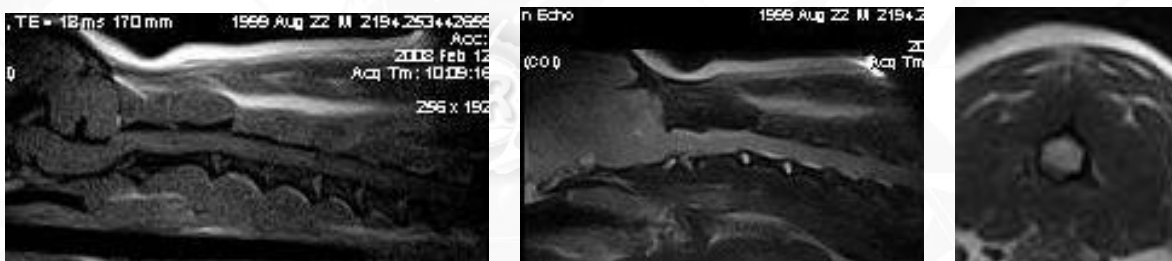
The images above show how transverse images should be positioned through the maximum width of the syrinx.

Poor quality images

The most common reason for a poor quality images is reduced acquisition time i.e. taking “short cuts”. The changes with early SM can be subtle and good quality images are required.



Examples of poor quality images from two CKCS obtained on an ESOVATE Vet MRI machine (above). Although it is possible to say that gross syringomyelia is absent, it is not possible to exclude the possibility of central canal dilatation especially as the submitting veterinary surgeon did not include transverse or sagittal images.

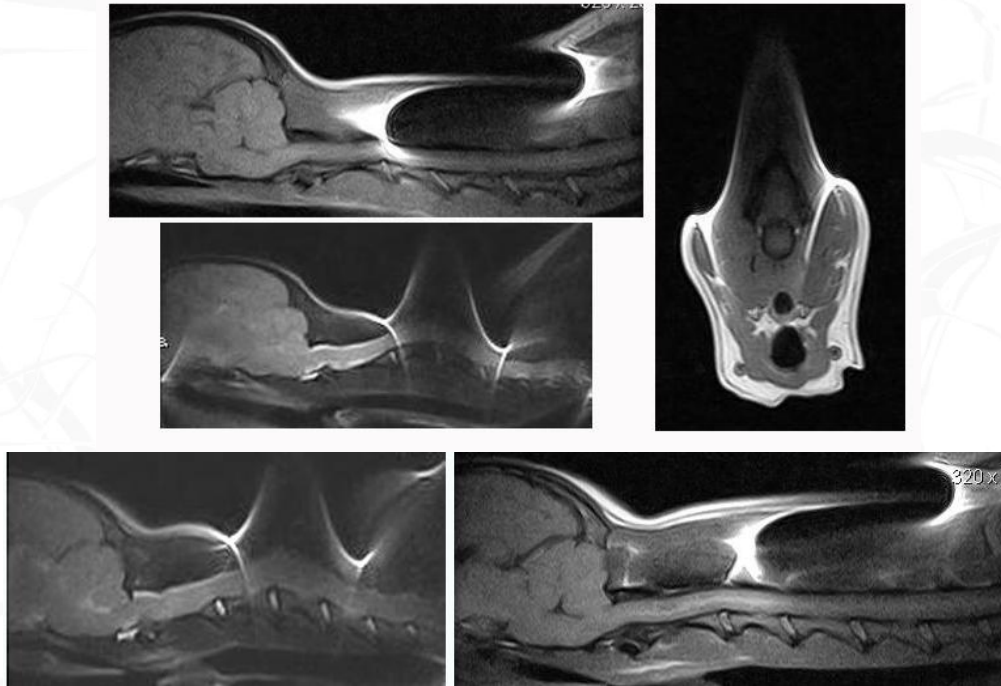


Examples of submitted poor quality images from a CKCS obtained on a 1Tesla machine. These images are completely non-diagnostic. In the T1W weighted imaged it is not possible to appreciate the CM (it looks milder than it actually is) and there is a possible central canal dilatation in C2 region which can be neither confirmed nor excluded from the T2W sagittal and transverse images.

Microchip is causing an artefact

If the microchip is causing the artefact (images below) there is little the operator can do. Microchips should be placed correctly; the standard site for microchip placement is in the subcutaneous tissue along the dorsal midline

(the spine) between the shoulder blades. For correct placement, the dog should be either standing or lying on his stomach. Some of the loose skin between the shoulder blades is gently pulled up, and the needle is quickly inserted. The applicator trigger is depressed, injecting the transponder or microchip into the tissues.



MRI images from a CKCS illustrating the distortion of the image from microchip placed under the skin in the neck.

How are the images submitted?

For more information visit www.bva.co.uk/chs and click on the “Canine Health Schemes”

1. the veterinary surgeon who has performed the MRI scan submits 2 CD copies of the DICOM images together with the part-completed CM/SM certificate, the owner having completed the Owner's Declaration and the veterinary surgeon having signed the Submitting Veterinary Surgeon's Certificate to certify –
 - a. the details regarding the submission of the MR images; and
 - b. the microchip or tattoo number once verified
2. The CDs may contain scans of more than one dog
3. The veterinary surgeon who is responsible for the MR scan should check that the breed, sex and colour of the dog correlate with those details in the Owner's Declaration and on the KC Registration Certificate. The veterinary surgeon should also check that the details on the KC Registration Certificate have been accurately and completely transposed by the owner onto the CMSM certificate i.e. the Kennel Club registered name, number, breed, sex, colour and date of birth.
4. For payment details see www.bva.co.uk/chs The BVA charge includes the scrutineers' fees, but **does not** cover the cost of MRI scanning.
5. The DICOM images are assessed by two scrutineers, from a panel appointed by the BVA. The scrutineers will agree grading for the images, and the completed and signed certificate and the CDs will be returned to the submitting veterinary surgeon; the certificate to be passed on to the owner of the dog.
6. If the scrutineers are unable to reach a consensus the images will be re-assessed by the Chief Scrutineer, whose decision is final.